



# ESDA

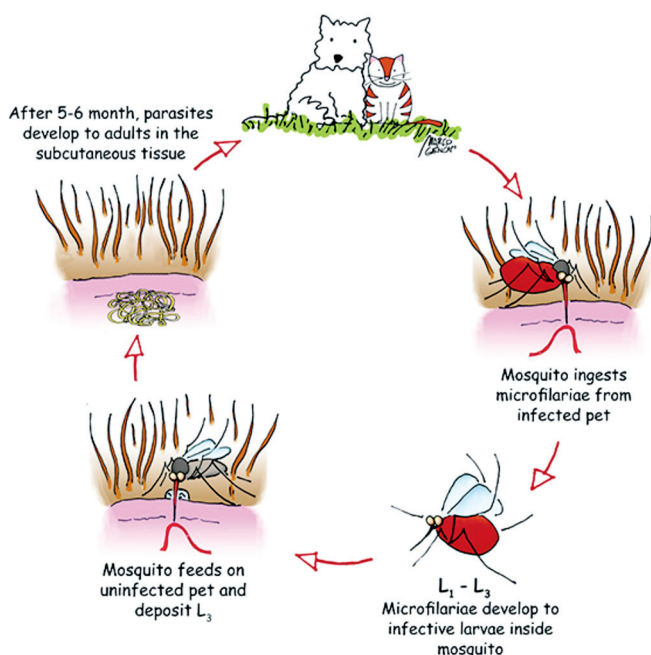
European Society of Dirofilariosis and Angiostrongylosis

## GUIDELINES FOR CLINICAL MANAGEMENT OF SUBCUTANEOUS DIROFILARIOSIS IN DOGS AND CATS

Prepared for and approved by the Executive Board of ESDA

Infection of dogs with *Dirofilaria repens* has been diagnosed in many European countries and is spreading. It is also currently considered one of the most important,

emerging zoonoses. These guidelines, developed by the European Society for *Dirofilaria* and *Angiostrongylus*, are based on the latest information and include up-to-date recommendations for the prevention, diagnosis, and clinical management of subcutaneous dirofilariosis.

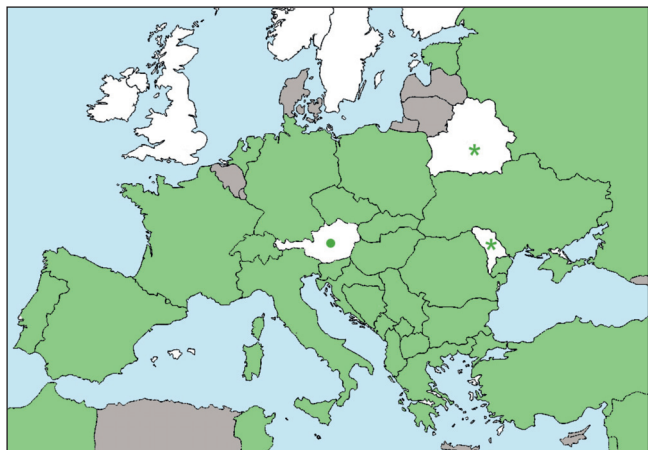


### Life cycle of *Dirofilaria repens*

Dogs and cats with subcutaneous dirofilariosis harbor adult parasites (females approximately 15 cms, males 7 cm) in subcutaneous tissue. Microfilariae are released, enter the bloodstream and are taken up by mosquitoes. Approximately 15 days later, larvae become infective  $L_3$  that are inoculated into a new host. Following several months of tissue migration, parasites complete their development and begin to release  $L_1$ .

### European Prevalence

The map below shows the European distribution of *D. repens* in dogs not receiving prophylaxis. Prevalence data for cats is lacking. The movement of infected hosts, the presence of competent mosquito vectors and climate



**Figure 1 - *Dirofilaria repens* in Europe.**  
 ★ DNA of the parasite found in mosquitoes; ● sporadic cases.

changes that allow the development and survival of mosquitoes for longer periods of the year all contribute to the spread of infection and disease. This is why it is so important to administer preventives during the transmission season. In some areas of Europe, this means year-round treatment (see section “Prevention”).

## Clinical signs of subcutaneous dirofilariosis

The majority of *D. repens*-infected animals remain asymptomatic. When present, the primary clinical sign is the presence of one or more skin nodules. They can be located in different anatomical sites and can measure from 0.5-3 cm. Sporadic reports of erythema, papules, alopecia and pruritus have also been described in dogs with natural *D. repens* infection, while one case of subcutaneous dirofilariosis mimicking a fibrosarcoma has been described in a cat.

It has been reported that nodules may show swelling after being handled (this should not be confused with the Darrier's sign typical of mast cell tumors).

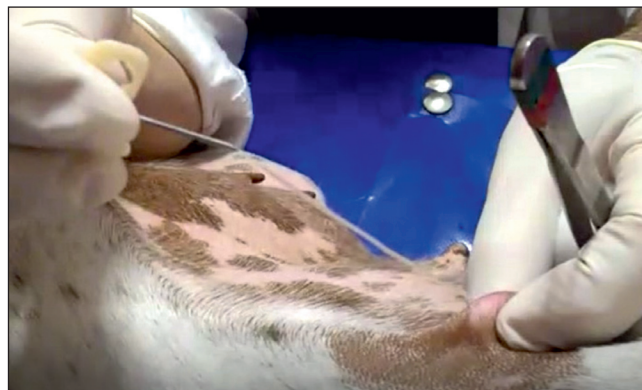Cytology by fine needle aspiration of nodules presents a mixed inflammatory infiltrate with or without a significant eosinophilic population. In many cases microfilariae, fragments of uteri from female nematodes and developing embryos can also be observed.

Ultrasound of nodules may show the typical double linear parallel hyperechoic structures indicative of filarial nematodes (Fig. 3).

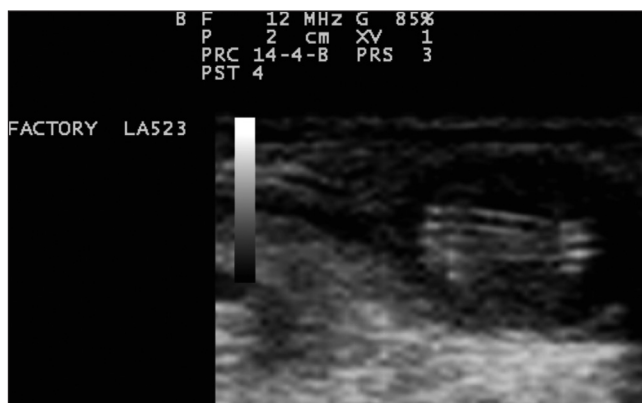On histology, nodules are granulomatous to suppurative and may contain cross-sections of filarial nematodes and/or microfilariae. The infiltrate is mainly composed of lymphocytes, macrophages, plasma cells, neutrophils and eosinophils in different proportions.

## Diagnosis

The hallmark of diagnosis for subcutaneous dirofilariosis is the observation of microfilariae larvae in blood. In asymptomatic infections, this is usually an accidental finding during routine blood smears or during screening for *D. immitis*. It is important to be able to distinguish



**Figure 2 - Surgical removal of an adult *D. repens* from a skin nodule, using the mini-invasive technique.**



**Figure 3 - Ultrasound of a skin nodule showing the typical double linear parallel hyperechoic structures.**

microfilariae of *D. immitis* from those of *D. repens*. Species of microfilariae in the blood, in the pellet from Knott test or membrane from filtration test can be confirmed by specific PCRs.

When one or more nodules are present, diagnosis can also be aided by cytology and ultrasound. Surgical removal and histology will confirm clinical suspicion.

How to perform a Knott test for the identification of *D. repens* microfilariae.

- Mix 1.0 mL of EDTA venous blood with 9.0 mL of 2% formalin in a conical centrifuge tube (a 2% formalin solution can be prepared diluting a standard 4% or 10% formalin solution for histology with distilled or tap water)
- Invert the tube gently 4 times to mix the solution
- Centrifuge for 3 minutes at 1500 rpm
- Pour off the supernatant and add 1-2 drops of 1% methylene blue and mix
- Place a drop of the sample on a glass slide and cover with a coverslip
- Examine the slide under the microscope at 10x to assess the presence of mf, and at 40x to observe the morphological features
- For maximum sensitivity, the whole sample should be analyzed.

For a step-by-step illustration of how to perform tests for the presence and identification of microfilariae, consult the ESDA website [www.esda.vet](http://www.esda.vet)

**TABLE 1 - MACROCYCLIC LACTONES USED FOR THE PREVENTION OF SUBCUTANEOUS DIROFILARIOSIS**

Drug	Administration	Dose	Interval	Efficacy against other ESDA parasites #
Ivermectin	Oral	> 6 mcg/kg	Monthly	<i>D. immitis</i>
Moxidectin	Injection Sr	0.17 mg/kg	Every 6-12 months	<i>D. immitis</i>
Moxidectin	Spot on	>2.5 mg/kg	Monthly	<i>D. immitis</i> , <i>A. vasorum</i>

At the labelled dose, all these drugs **are safe** in dogs that **are sensitive to MLs** due to the presence of the so-called Multidrug Resistant 1 mutation (for example, Collies, Australian shepherd).

# Prophylactic activity against *D. immitis* or *A. vasorum*. Some drugs alone or in combination are active against other endo or ectoparasites.

## Treatment

There is currently one drug registered for the adulticide treatment for *D. repens*. Monthly treatments with moxidectin + imidacloprid spot-on (Advocate®) is licensed for adulticide treatment, microfilaria reduction and prevention in dogs (see below).

In case of subcutaneous nodules worms can be minimally invasive removed without any sedation with a 19 G needle connected to a syringe creating vacuum inserted into the nodule (Fig. 1).

Because of the zoonotic potential, microfilaraemic dogs should be treated monthly for 12 months with drugs active against microfilariae.

## Prevention

Prevention of *D. repens* is very important not only to avoid clinical disease in pets, but also to protect public health.

*D. repens* infection can be prevented by the administration of macrocyclic lactones that are able to eliminate infective larvae up to 30 days old. Thus, the monthly administration will kill all the larvae that mosquitoes have inoculated in the previous 30 days. There are currently drugs that are registered for the prevention of *D. repens* infection and *D. immitis* together.

The use of topical synthetic pyrethroids (i.e. permethrin), applied monthly, has been reported as significantly decreasing the risk of mosquitoes bites in dogs (so-called “anti-feeding” effect). **The use of pyrethroids does not substitute the use of MLs**, but it can be combined with macrocyclic lactones to lessen the risk of infection in the case of missed administration of an ML or in cases of lack of compliance of the owner (“double defense”).



All rights reserved.

No part of this publication may be reproduced, stored in a retrieval system, or internet communication system or transmitted in any form, or by any means, electronic, mechanical, photocopying, recording or otherwise, without the prior permission, in writing, from the publisher.

© Copyright 2017 - EV/ESDA